Osteochondral Allograft for treatment of cartilage defects of the metatarsal head

John G. Fleischli, DPM, FACFAS Terese J. Laughlin, DPM, FACFAS Jeffery W. Fleischli, DPM, FACFAS

Foot & Ankle Associates of Central Illinois, LLC Springfield, Illinois

Introduction

- Osteoarthritis (OA) affects nearly 21 million people in the United States accounting for 25% of visits to primary care physicians, and half of all Non-Steroidal Anti-Inflammatory Drugs prescriptions. [1]
- It is estimated that 80% of the population will have radiographic evidence of OA by age 65. [1]
- In the United States, hospitalizations for OA increased from about 322,000 in 1993 to 735,000 in 2006. [1]
- OA of the first metatarsophalangeal joint (Hallux Rigidus) is most common osteoarthritic joint in the foot, and the second most common great toe condition behind Hallux Valgus. [2]
- One in forty individuals over 50 years of age develop Hallux Rigidus with females twice as likely to be affected. [1-3]

Surgical Treatment of Hallux Rigidus

- Most patients will attempt multiple conservative efforts to relieve pain associated with Hallux Rigidus. However, most of these treatments fail to completely relieve pain, and patients often proceed to surgical intervention.[4-7, 4, 5]
- The goal surgical intervention is to reduce pain, resect osteophytic bone, and restore joint motion.[6, 8-10]
- The literature remains unclear regarding the most appropriate treatment for all stages of Hallux Rigidus, with no procedure considered the gold standard.[6, 8, 9, 11]
- The Cheilectomy and Valenti procedures are often recommended for mild to moderate pathology and, consists of resection of hypertrophic bone at the joint in order to increase motion, and relieve dorsal impingement. The literature has demonstrated success with this procedure and other similar procedures, for the more mild or moderate cases of Hallux Rigidus when the articular cartilage damage is less involved. [10, 12-14]
- Osteochondral transplants (OATS) have been used in large joints successfully, but are rarely used in the foot.[15]

Rational for OATS Procedure of the Great Toe

- While the Cheilectomy and Valenti procedures remains popular among foot and ankle surgeons, there is a commonly held belief that this procedure is best used in the earlier stages of joint disease. [16-18]
- A procedure which combines the ease and effectiveness of the Cheilectomy with repair of cartilage damage would, in theory, offer a more beneficial procedure for the treatment of Hallux Rigidus.
- The OATS procedure offers the surgeon the ability to replace of the damaged articular surface.
- The transplant of cartilage should reduce the stress associated with OA and slow the development of bone changes typically seen as the disease process continues. Ultimately, this should offer the patient a better outcome as the pathological process is reduced by replacing the protective layer of cartilage.
- The use of the osteochondral transplant should allow all stages of the disease process to be addressed when combined with a traditional Cheilectomy or Valenti procedure.
- The degenerative process of Hallux Rigidus follows a typical pattern of progression. The articular cartilage damage begins on the dorsal surface of the joint and moves in a plantar direction with time.[6] The success of the Cheilectomy / Valenti procedure is achieved by removing ectopic bone and a portion of the dorsal joint surface which has been denuded of cartilage.[10, 12, 13]]

Methods

- We retrospectively identified patients who underwent surgical treatment with osteochondral allograft of the metatarsal head. Particular attention was given to those patients in whom an OATS procedure was combined with a Cheilectomy / Valenti procedure.
- The following information was collected for each patient:
  - ⇒ Pre and Post-operative range of motion; using a standard technique. [19]
  - ⇒ Reduction of pain associated with the degenerative joint.
  - ⇒ Successful radiographic incorporation of the allograft
  - ⇒ Patient satisfaction with the procedure.
- We evaluated the change in post-operative range of motion (dorsiflexion, plantarflexion, and total range of motion) statistically using a paired t-test. Patients were included in the evaluation of range of motion if they were at least 5 weeks post-op.
- All results were analyzed with a p value less than 0.05 to be considered statically significant.

Results

- No complications with any of the procedures were noted.
- No post-operative infections occurred
- All radiographs demonstrated complete incorporation of the allograft by week 5.
- All patients expressed satisfaction with the procedure.
- All patients reported reduction in pain with one patient experiencing pain and stiffness several months post-op. This patient was treated with a corticosteroid injection, and reported no further problems,.
- One patient had an acute chondral injury to the first metatarsal head (confirmed by MRI evaluation) without any other evidence of joint degeneration. Therefore, an isolated OATS procedure was performed without bone resection.

Patient Demographics

Total Number of Patients:	N = 19
Number of Patients Evaluated for ROM :	N = 14
Sex:	7 Male
Mean BMI:	28
Smokers:	N = 3
Mean Patient Age:	54 (32 - 70)

Implant Information

Total Number of Implants:	22
Mean Size Implant 1st Metatarsal (N = 14):	9 mm (7 - 10)
Mean Size of Implant 2nd Metatarsal (N = 2):	7 mm
Mean Size of Implant Proximal Phalanx (N = 3):	7 mm

Dorsiflexion Range of Motion Hallux Rigidus Patients

Paired t-test:
Normality Test: Passed (P = 0.230)

Treatment Name	N	Mean	Std Dev	SEM
Pre-Op Dorsiflexion	14	35.500	12.787	3.417
Post-Op Dorsiflexion	14	58.429	6.321	1.689
Difference	14	-22.929	10.307	2.755

t = -8.324 with 13 degrees of freedom. (P = <0.001)

95 percent confidence interval for difference of means: -28.879 to -16.978

The change that occurred with the treatment is greater than would be expected by chance; there is a statistically significant change (P = <0.001)

Power of performed test with alpha = 0.050: 1.000

Plantarflexion Range of Motion Hallux Rigidus Patients

Paired t-test:
Normality Test: Passed (P = 0.184)

Treatment Name	N	Mean	Std Dev	SEM
Pre-Op Plantarflexion	14	5.571	2.738	0.732
Post-Op Plantarflexion	14	8.286	4.762	1.273
Difference	14	-2.714	4.615	1.233

t = -2.201 with 13 degrees of freedom. (P = 0.046)

95 percent confidence interval for difference of means: -5.379 to -0.0498

The change that occurred with the treatment is greater than would be expected by chance; there is a statistically significant change (P = 0.046)

Power of performed test with alpha = 0.050: 0.433

The power of the performed test (0.433) is below the desired power of 0.800

Total Range of Motion Hallux Rigidus Patients

Paired t-test:
Normality Test: Passed (P = 0.673)

Treatment Name	N	Mean	Std Dev	SEM
Pre-Op Range of Motion	14	41.071	14.046	3.754
Post-Op Range of Motion	14	66.857	8.132	2.173
Difference	14	-25.786	12.380	3.309

t = -7.793 with 13 degrees of freedom. (P = <0.001)

95 percent confidence interval for difference of means: -32.934 to -18.638

The change that occurred with the treatment is greater than would be expected by chance; there is a statistically significant change (P = <0.001)

Power of performed test with alpha = 0.050: 1.000

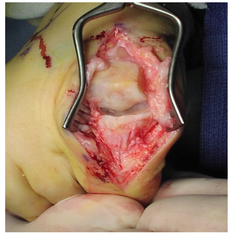

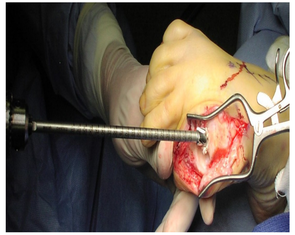

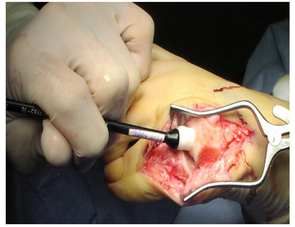

Discussion

- While osteochondral transplants have been described in the metatarsal, [20-23] this represents the first series of allograft osteochondral transplant used in the treatment of OA of the metatarsal head.
- We report the first series of patients in which a Cheilectomy / Valenti procedure was performed with the addition of an osteochondral transplant (OATS procedure).
- In our series, all patients received an allograph osteochondral implant, with good success. No complications were noted.
- Statistical significant changes were noted in postoperative range of motion. This included dorsiflexion, plantarflexion and total range of motion.
- We theorize that the osteochondral transplant will further the success of the Cheilectomy / Valenti procedure by increasing the amount of viable cartilage within the joint.
- Increasing cartilage should further reduce recurrence rates, increase patient satisfaction, and increase the number of patients in which a Cheilectomy / Valenti procedure can be used.
- The procedure can be used in the more advanced phases of Hallux Rigidus with recovery in much the same manner as the Cheilectomy / Valenti alone, despite the more advanced disease process.
- This investigation represents pilot data and further investigations are warranted.

Conclusions

- The OATS technique, in combination with a resection of the dorsal joint surface (Cheilectomy / Valenti) allows the surgeon the freedom to perform a joint sparing procedure for the more advanced cases of Hallux Rigidus.
- The OATS procedure is a good option for Hallux Rigidus as it allows a true hyaline cartilage replacement. This should more closely mimic the natural joint surface.
- The procedure does not preclude us from returning for a revision procedure, including an implant and/or arthrodesis if the patient should progress and continue to have problems.
- This represents the first reported series of patients in which a Cheilectomy / Valenti procedure was successfully used in conjunction with an allogenic osteochondral transplant.

References

1. Quality AfHRa. *Statistics on Hospital-Based Care in the United States*. Washington: Department of Health and Human Services: Healthcare Cost and Utilization Project; 2006-2006.
2. Gould N, Schneider W, Ashikaga T. Epidemiological survey of foot problems in the continental United States: 1978-1979. *Foot & Ankle*. July 1980;1(1):8-10.
3. Wheeless CR. *Wheeless' Textbook of Orthopaedics*: Data Trace Internet Publishing, LLC; 2008.
4. McMaster M. The Pathogenesis of Hallux Rigidus. *J Bone and Joint Surg Br*. 1978;60B(1):82-87.
5. Nawoczenski DA. Nonoperative and Operative Intervention for Hallux Rigidus. *Journal of Orthopaedic & Sports Physical Therapy*. 1999;29(12):727-735.
6. Coughlin MJ, Shurnas PS. Hallux rigidus: demographics, etiology, and radiographic assessment. *Foot Ankle Int*. 2003;24(2):167-83.
7. Grady JF, Axe TM, Zager EJ, Sheldon LA. A Retrospective Analysis of 772 Patients with Hallux Limitus. *J Am Podiatr Med Assoc*. 2002;92(2):102-108.
8. Benson P, Phillips C, Cort S. Classification Systems for Hallux Rigidus: A Review of the Literature. *Foot & Ankle International*. April 2008;29(4):407-414.
9. Vanore JV, Christensen JC, Kravitz SR, et al. Diagnosis and Treatment of First Metatarsophalangeal Joint Disorders. Section 2: Hallux Rigidus. *Journal of Foot & Ankle Surgery*. May/June 2003;42(3):124-136.
10. Kurtz DH, Harrill JC, Raczauskas BI, Solomon MG. The Valenti procedure for hallux limitus: a long-term follow-up and analysis. *J Foot Ankle Surg*. Mar-Apr 1999;38(2):125-130.
11. Easley ME, Davis WH, Anderson RB. Intermediate to long-term follow-up of modified-approach dorsal cheilectomy for hallux rigidus. *Foot Ankle Int*. Mar 1999;20(3):147-152.
12. Hattrup SJ, Johnson KA. Subjective results of hallux rigidus following treatment with cheilectomy. *Clin Orthop Relat Res*. Jan 1988;228:182-191.
13. Lee KB, Park YW, Jung ST, Park JS, Suh JS. Long-term outcomes of modified cheilectomy for severe hallux rigidus. *Foot Ankle Int*. Jan 2008;29(1):7-11.
14. Gerbert J. Hallux Limitus/Rigidus. In: Joshua Gerbert D, ed. *Textbook of Bunion Surgery*. 2nd ed. Mount Kisco: Futura Publishing Company Inc.; 1991:455-492.
15. Revell C, Athanasiou K. Success Rates and Immunologic Responses of Autogenic, Allogenic, and Xenogenic Treatments to Repair Articular Cartilage Defects. *Tissue Eng Part B Rev*. 2008 2008;Epub ahead of print(Dec 8).
16. Durrant MW, Sieper KB. Role of soft tissue structures as an etiology of hallux limitus. *J Am Podiatr Med Assoc*. 1993;83(4):173-180.
17. Gerbert JJ, Rock GD, McGrath MP. Mancuso JE. Cheilectomy Still a Useful Technique for Grade I and Grade II Hallux Limitus/Rigidus. *J Foot Surg*. April 1992;31(2):154-159.
18. Hetherington VJ. Hallux rigidus: a review of its aetiology. *Foot Ankle Int*. Jan 1995;16(1):43-48.
19. Bush T, Green DR, Alvine J. Measurement of the First Metatarsophalangeal Joint Range of Motion. *J Am Podiatr Med Assoc*. 1988;78:459-468.
20. DeVries JG, Amini RA, Cummings P, Sockrider N. Freiberg's infraction of the second metatarsal treated with autologous osteochondral transplantation and external fixation. *J Foot Ankle Surg*. Nov-Dec 2008;47(6):565-570.
21. Mizumoto W, Takao M, Uchio Y, Kono T, Ochi M. Late-stage Freiberg disease treated by osteochondral plug transplantation: a case series. *Foot Ankle Int*. Sept 2008;29(9):950-955.
22. Title CI, Zaret D, Means KRJ, Vogrman J. First metatarsal head OATS technique: an approach to cartilage damage. *Foot Ankle Int*. Nov 2006;27(11):1000-1002.
23. Tsuji M, Hasegawa M, Hirata H, Uchida A. Subchondral insufficiency fracture of the second metatarsal head in an elderly woman treated with autologous osteochondral transplantation. *Arch Orthop Trauma Surg*. Jul 2008;128(7):689-693.

This investigation performed with financial support from Arthrex Inc.