Parallel Fixation Method with Early Weight Bearing Following Lapidus Arthrodesis

John G. Fleischli, DPM, FACFAS Terese J. Laughlin, DPM, FACFAS Jeffery W. Fleischli, DPM, FACFAS

Foot & Ankle Associates of Central Illinois, LLC

Introduction

- The treatment of hallux abducto-valgus deformity (HAV) is common among practitioners treating the lower extremity. The goal of treatment, regardless of surgical procedure, is to correct the deformity and reduce pain.[1-4]
- First metatarsal-cuneiform arthrodesis (Lapidus Arthrodesis) is popular for the correction of hallux valgus deformity.[3] Traditional fixation techniques require prolonged periods of non weight bearing including suture, Kirschner wires, screws, and plates. [3, 4]
- Screw fixation is an important component of the 1st metatarsal-cuneiform arthrodesis, and can be considered the standard of care.[3, 5] Screw fixation offers good bone-to-bone contact with interfragmental compression and primary bone healing. [5-7] Wheeler and McLoughlin demonstrated that a fully threaded compression screw (Acutrak ®; from Acumed LLC: Hillsboro, OR) is capable of producing and maintaining compression between bone fracture fragments. In addition, the Acutrak screw was shown to have superior mechanical characteristics as compared to other headless screws in every mode tested.[8]
- Incorporating plate fixation stabilizes the arthrodesis site, yet most surgeons agree plate fixation alone is not optimal. [5-7] Gruber *et al* speculates that the addition of the compression screw across the fusion site in combination with plate fixation achieves interfragmentary friction and neutralizes plantar tensile forces.[6] Position of the plate for the Lapidus arthrodesis varies in published reports.[5, 6, 9, 10] While medial placement over the joint remains popular, this position does not resist the forces of weight-bearing (torsional and sagittal plane) adequately. [9] Optimal plate position would be on the plantar surface of the arthrodesis site, yet this is not practical due to technical difficulties. [11]
- Traditional post operative care includes non-weight bearing for up to six weeks. [3] More recently, early ambulation with full weight bearing has been described with success. [12] To assure complete union of the arthrodesis site, extremely stable fixation is advisable. Klos *et al* used locking (fixed-angle) plates to allow earlier resumption of weight bearing and improve bony union with the Lapidus procedure [9]
- We theorize that the combination of a plantar headless compression screw with dorsal plating will produce the needed compression and stabilization following a Lapidus arthrodesis to allow immediate protected weight bearing with predictable and consistent results.
- We retrospectively evaluated patients treated for hallux valgus deformity with a Lapidus type arthrodesis using a combination of plantar headless compression screw with dorsal plating.
- The degenerative process of Hallux Rigidus follows a typical pattern of progression. The articular cartilage damage begins on the dorsal surface of the joint and moves in a plantar direction with time.[6] The success of the Cheilectomy / Valenti procedure is achieved by removing ectopic bone and a portion of the dorsal joint surface which has been denuded of cartilage.[10, 12, 13]

Methods

- All patients underwent a Lapidus type arthrodesis as described by Toolan. [3] Joint preparation was consistent between patients.
- Fixation of the arthrodesis was achieved using two points of fixation. The first being a large headless compression screw (Acutrak ®; from Acumed LLC: Hillsboro, OR) placed from the plantar aspect of the 1st metatarsal crossing the arthrodesis site into the medial cuneiform. The screw was oriented in a slight dorsiflexion direction. If it was deemed necessary the screw was passed through the medial cuneiform into the intermediate cuneiform.
- The second point of fixation consisted of a three or four hole plate placed dorsally. The plate was roughly parallel to the orientation of the plantar screw in the sagittal plane. If the surgeon felt it necessary, a second headless compression screw was placed through the dorsal plate in a crossing fashion with the plantar screw (plantar orientation)
- All patients received pre-operative antibiotic prophylaxis.
- Post-operative protocol included immediate weight-bearing in a cast boot until complete radiographic union was noted (4-6 weeks), followed by transition to athletic style shoes.

This investigation performed with financial support from Acumed LLC.

Study Design

Patients who underwent a Lapidus arthrodesis were identified by CPT code and evaluated retrospectively using chart review. Patients meeting the following criteria were included:

1. A complete medical record.
2. Lapidus arthrodesis using Acutrak ® screw fixation with dorsal plate fixation
3. Pre-operative and healed post-operative weight-bearing radiographs.

The patient records were reviewed for the following data:

1. Radiographic union of the arthrodesis site as defined by complete radiographic union and lack of a plantar gap as described by Klos *et al*. [9]
2. Complications associated with hardware including removal, delayed union or non-union.
3. Measurements of pre and post-operative intermetatarsal angle using the Mitchell method.[13]
4. Post-op infections as defined by the need for post-operative antibiotics.
5. Patient age, body mass index (BMI), sex, smoking history, and diabetic history.

Results

- 23 patients were identified with 20 (4 male) meeting inclusion criteria. All patients healed without major complication. Good radiographic and clinical union was seen in all patients. No plantar gapping was noted in the group. One minor complication occurred (delayed union), but this subsequently healed with the addition of a bone stimulator and is symptom free. The average pre-operative intermetatarsal angle was 14.25 and the average post-operative angle was 7.85 for an average reduction of 6.40 degrees.
- 18 patients underwent adjunctive procedures with the 2nd metatarsal osteotomy (Weil Type) predominating. The average number of office visits was 6.6 (range 5 - 9). Patients were followed for an average of 12.15 weeks (range 8 - 20).
- Three patients experienced hardware issues (painful) and underwent hardware removal (two screws and one screw / plate). No infections were noted.
- One patient was an active smoker and three were former smokers. There was one well controlled type II diabetic in the group. No complications or hardware issues were noted among the smokers or the diabetic patient.

										Post Op				
Patient	Age	Ht	Wt	BMI	Sex	Diabetes	Smoking History	Hardware Removal	Instrument Removed	Pre Op IM Angle	IM Angle	IM Reduction	Adjunctive Procedure	Complications
1	30	62	200	37	Female	No	Yes	No		18	11	7	Yes	
2	62	63	172	30	Female	No	No	Yes	Screw	14	8	6	Yes	
3	55	60	130	25	Female	No	No	No		11	6	5	Yes	
4	18	70	130	19	Male	No	No	No		15	8	7	No	
5	71	62	129	24	Female	No	No	Yes	Screw/Plate	15	9	6	Yes	
6	46	69	230	34	Female	No	No	No		12	8	4	Yes	Delayed Union
7	54	64	138	24	Female	No	Quit	No		12	5	7	Yes	
8	54	64	138	24	Female	No	Quit	No		12	7	5	Yes	
9	31	70	245	35	Male	No	Quit	No		15	11	4	Yes	
10	53	64	118	20	Female	No	No	Yes	Screw	14	8	6	Yes	
11	39	64	160	27	Female	No	No	No		15	8	7	Yes	
12	14	60	84	16	Female	No	No	No		17	10	7	No	
13	16	61	101	19	Male	No	No	No		14	7	7	No	
14	41	72	235	32	Male	No	No	No		11	7	4	Yes	
15	61	66	150	24	Female	No	No	No		18	10	8	Yes	
16	14	64	104	18	Female	No	No	No		11	6	5	Yes	
17	29	64	185	32	Female	No	No	No		13	8	5	Yes	
18	39	66	200	32	Female	No	No	No		17	8	9	Yes	
19	37	64	330	57	Female	Yes	No	No		17	8	9	Yes	
20	51	66	150	24	Female	No	No	No		14	4	10	Yes	

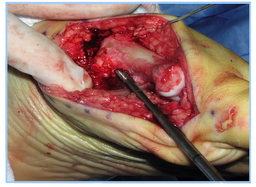

Plantar Acutrak Screw Placement

AP radiograph demonstrating plantar screw with parallel dorsal plate with second interfragmental compression screw dorsally.

Dorsal Parallel Plate Placement

A Second Acutrak Screw Placed Through the Dorsal Plate

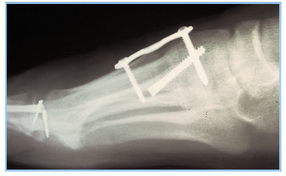

Lateral radiograph demonstrating plantar screw with parallel dorsal plate.

Lateral radiograph demonstrating plantar screw, parallel dorsal plate, with second interfragmental compression screw through the dorsal plate

Discussion

- Non healing rates for 1st metatarsal-cuneiform arthrodesis treated non-weight bearing have been reported to be 3%-12%. [14] In this retrospective evaluation of 20 patients allowed immediate ambulation found superior results with no non-unions and 1 patient (5.3%) experiencing delayed union.
- Parallel fixation is achieved by placing a compression screw along the plantar arthrodesis site in combination with dorsal plate. This allows the strongest compressive forces at the plantar surface where failure usually occurs as demonstrated by plantar gapping. The dorsal plate resists the torsional and sagittal plane forces of weight bearing.
- The primary screw choice is also important. The Acutrak screw provides compression along the entire length of screw. This design makes it an excellent choice for fixation.
- We believe parallel screw and plate fixation of 1st metatarsal-cuneiform arthrodesis offers an excellent alternative to previously described fixation techniques.
- Gruber *et al* felt that friction between the bones was an important part of stability surrounding the Lapidus arthrodesis site. They noted that early studies, in which the plate fixation alone was found to be inferior to screw fixation were a result of poor compression between the bones. Screw fixation demonstrated superior stability in cadaver models. [6] We speculate that the combination of screw and plate fixation would allow better outcomes. The plantar placement of the screw offers stability, compression and friction between the bone ends, while better resisting the sagittal plane forces of weight bearing. The dorsal plate to further stabilizes the arthrodesis in the sagittal plane and helps neutralize the torsional forces.
- While plate fixation has become common place in many procedures including the Lapidus arthrodesis, the orientation of the plate remains a matter of debate. [5, 7, 9, 10, 15] This has become especially important when allowing early ambulation post-operatively. While the plantar placement of the plate offers the best opposition to weight bearing stress, [11] the technique required is difficult. We therefore used the dorsal placement of a plate in combination with plantar screw fixation. This dorsal plating allows good reduction of the weight bearing forces with easy placement of the plate. Dorsal plating has been found superior in other joints of the foot, [16] but remains less commonly used in the Lapidus arthrodesis. The plantar surface of the arthrodesis site will undergo significant forces with weight bearing. These forces will tend to displace the plantar arthrodesis site (plantar gapping) if not controlled. [7, 9] Therefore, fixation on the plantar surface is warranted, and the screw fixation is easy to insert, and can be orientated across the 1st metatarsal intermediate cuneiform articulation as well if so desired.
- We feel that the parallel nature of the screw and plate is advantageous. In other joints, research has demonstrated that parallel fixation offers superior resistance to torsional forces when compared to orthogonal fixation. [17] While the forces of weight bearing in the area would primarily lie within the sagittal plane, rotational forces remain on the 1st ray. [7, 9] Parallel fixation reduce rotational forces and thus would serve to further stabilize this arthrodesis site.

Conclusions

We found that a combination of a plantar screw with a dorsal plate offers excellent fixation of the Lapidus arthrodesis in a small retrospective evaluation. The parallel nature of the two types of fixation, in combination with good bone to bone compression and resistance to sagittal (weight bearing) forces allows immediate ambulation. Our complication rate was lower than the reported literature.

References

1. Gilbert R, Sparkes CN, Alay AE, Robins O, Tabak Y. Range of Motion of the First Metatarsophalangeal Joint After Chevron Procedure Reinforced by a Modified Capsulotomy. *Journal of Foot and Ankle Surgery* (Jan. 1998) 37(1):24-29; discussion 71-2.
2. Laughlin TJ. Complications of distal first metatarsal osteotomies. *J Foot Ankle Surg.* Nov-Dec 1995;34(6):524-531.
3. Toolan BC. Surgical Strategies: The Lapidus Procedure. *Foot & Ankle International*. October 2007;28(10):1109-1114.
4. Ray JJ, Friscia A, Cohen I. Lapidus Arthrodesis for the Treatment of Hallux Rigidus Deformity: A Review and Meta-Analysis. *Foot & Ankle Specialist*. June 2009;2(3):143-150.
5. Scranton PE, Coetzee JC, Carreira D. Arthrodesis of the First Metatarsocuneiform Joint: A Comparative Study of Fixation Methods. *Foot & Ankle International*. April 2009;30(4):341-347.
6. Gruber KA, Delaney JA, Bae S-T, Parks BG, Schon LC. Crossed Screws Versus Dorsomedial Locking Plate with Compression Screw for First Metatarsocuneiform Arthrodesis: A Cadaver Study. *Foot & Ankle International*. September 2008;29(9):927-930.
7. Coiner DA, Parks BG, Schon LC. Screw Fixation Compared to H-Locking Plate Fixation for First Metatarsocuneiform Arthrodesis: A Biomechanical Study. *Foot & Ankle International*. November 2006;27(11):1000-1004.
8. Wheeler D, McLoughlin S. Biomechanical assessment of compression screws. *Clinical Orthopaedics and Related Research*. January 2008;470:315-318.
9. Klos K, Gueorguiev B, Mueller T *et al*. Stability of Medial Locking Plate and Compression Screw Versus Two Crossed Screws for Lapidus Arthrodesis. *Foot & Ankle International*. 2010;31(3):257-261.
10. DeVries JG, Gaston JD, Hyer CF. Fixation of First Tarsometatarsal Arthrodesis: A Retrospective Comparative Cohort of Two Techniques. *Foot & Ankle International*. 2011;32(2):158-162.
11. Marks RM, Parks BG, Schon LC. Midfoot fusion technique for neuroarthropathic foot: biomechanical analysis and rational. *Foot & Ankle International*. 1998;19:207-212.
12. Boyle P, Croft EA, Cook JJ. Immediate Weight Bearing Following Modified Lapidus Arthrodesis. *JFAS*. 2010;49:459-464.
13. Mitchell CL, Fleming JL, Allen B, Glenney C, Sanford GA. Osteotomy-Instrumentcrimp for hallux valgus. *Journal of Bone and Joint Surgery* (Am). 1958;40:41-60.
14. Thompson JM, Behrle DM, Anderson JG. Fusion Rate of First Tarsometatarsal Arthrodesis in the Modified Lapidus Procedure and Flatfoot Reconstruction. *Foot & Ankle International*. 2010;31(10):882-886.
15. Saxena A, Nguyen A, Nelson E. Lapidus Bunionectomy: Early Evaluation of a Crossed Leg Screws versus Locking Plate with Plantar Leg Screw. *Journal of Foot & Ankle Surgery*. March 2009;48(2):170-175.
16. Kumar S, Pradhan R, Rosenfeld PF. First Metatarsophalangeal Arthrodesis Using a Dorsal Plate and a Compression Screw. *Foot & Ankle International*. 2010;31(9):797-801.
17. Zalavras CG, Vancilis MT, Jan RI, Ouzounkilari K, Sumen IM, Lin TQ. Biomechanical evaluation of parallel versus orthogonal plate fixation of intra-articular distal humeral fractures. *J Shoulder Elbow Surg*. Jan 2011;20(1):12-20.